



Review Article

A CRITICAL REVIEW ON *KARNINI YONIVYAPAD* W.S.R. TO CERVICAL EROSION

Sonika Pal^{1*}, Chandra Prakash²

¹Assistant Professor, Dept. Prasututantra, ²Assistant Professor, Dept of Kayachikitsa, Dhanvantri Ayurvedic Medical College, Bareilly, Mathura, India.

Article info

Article History:

Received: 13-03-2018

Accepted: 06-04-2018

KEYWORDS: *Cervical*

Erosion, Ayurved, Yonivyapad, Karnini.

ABSTRACT

God has blessed the woman with most valuable gift of motherhood. A healthy woman can make healthy family and ultimately maker of healthy nation. Henceforth disease which causes physical or psychological concern to a woman should be immediately taken care of and so equally weighed in medical science. Cervical erosion is one of the most commonest gynaecological condition seen in OPDs. About 80% of women among her reproductive age group are suffering from this problem. Clinically it is defined as the development of red velvety area on the portio vaginalis around the external os. In Ayurvedic classical texts almost all the gynaecological disorders comes under the term '*Yonivyapad*'. All the classics have given the number of *Yonivyapad* as twenty. '*Karnini yonivyapad*' is one among of them. According to Acharya Charaka. Due to straining during labour in the absence of labour pains, the *Vayu* obstructed by fetus, with holding *Kapha* and getting mixed with *Rakta* produces '*Karnika*' in *Yoni*, which obstructs the passage of *Rakta* (*Raja*). Due to presence of *Karnika* this condition is termed as '*Karnini*'. In the present article Ayurvedic review of '*Karnini Yonivyapad*' has been correlated with 'Cervical erosion' in Modern review on the basis of morphological and physiological symptoms. Hence the description of '*Karnini yonivyapad*' seems to be nearer to cervical erosion.

*Address for correspondence

Dr Sonika Pal

H.N. 112, Mohalla Takhan near
Novelty Talkies, Pilibhit- 262001,
U.P.

Email: sonika2007pbt@gmail.com

Mobile- 7976033713

INTRODUCTION

According to Acharya Charaka due to straining during labour in the absence of labour pains means *Akala*, the *Vayu* obstructed by fetus, with holding *Kapha* and getting mixed with *Rakta* produces *Karnika* in *Yoni*, which obstructs the passage of *Raja*. due to presence of *Karnika* this condition is termed as *Karnini*.

Acharya Sushruta explains the pathogenesis of this disease in a different manner he describes that vitiated *Kapha* along with *Rakta* produces *Karnika* in the *yoni*.

Both the Vagbhata have followed Charaka. Acharya Indu, commentator of Ashtanga sangraha while clarifying the description says that due to premature ejaculation of fluid brought about by untimely straining leads to vitiation of *Vata*, aggravated *Vata* with holding *Kapha* and *Rakta* produces '*Karnika*' on '*Garbhashaya dwara mukha*' which obstructs the passage of *Raja*.

Madhava Nidana Bhavaprakasha and Yogaratnakar has followed Sushruta

Etymology of *Karnini*

Literally the word '*Karnini*' is derived from '*Karnin*' which refers to 'having ear' or 'relating to ear', 'barbed' or 'furnished with knots' etc.

The disease got its name due to development of '*Karnika*' on *Garbhashaya dwara mukha*. *Karnika* means 'round protuberance', 'pericarp of lotus', small brush' and 'tip of an elephant's trunk.

On the basis of etymology of disease i.e. '*Karnini*' or its clinical features i.e. development of '*Karnika*' on *Garbhashaya dwaramukh*, it appears to be a muscular structure covered with small sprouts or knots, growing over cervix.

Definition of *Karnika*

In classics, *Karnika* described as a singular growth of *Mansa* and several *Mansankur* like pericarp of lotus.

Indu, the commentator of Ashtang Sangraha has mentioned the place of origin as *Garbhashaya-dwar mukha* i.e. cervix.

Correlation between word '*Karnini*' of *Karnini yonivyapad* with gynaecological disorders mentioned in modern science is -

Cervical Erosion

Karnini can be compared with cervical erosion. In cervical erosion the cervix becomes somewhat hypertrophid, congested and covered with small red projection resembling sprouts (described by Indu), this erosion is often associated with nabothian cysts which are small pea sized smooth nodulas structures, thus due to presence of small sprouts the cervix assumes the shape of barbed wire or small brush and when associated with nabothian cysts then assumes to the pericarp of lotus.

Nidana (Etiology) of *Karnini Yonivyapada*

Nidana of *Karnini Yonivyapad* describe under two headings as -

1. *Samanya Nidana*
2. *Vishista Nidana*.

1. *Samanya Nidana*

It comprises all the *Nidan* those are responsible for all *Yonivyapada* including *Karnini Yonivyapada*. Acharya charaka mentioned in Chikitsa sthana that no any *Yonivyapada* occurs without vitiation of *Vata*. It means all the factors which causes vitiation of *Vata* are directly or indirectly are causative factor for *Yonivyapada*.

Further he describe *Samanya nidana* of *Yonivyapada* as abnormal dietics and abnormal mode of life abnormal *Artava* abnormalities of *Bija* (sperm and ovum) and *Daiva* are the factor leading to various *Yonivyapada*.

Acharya Sushruta correlating the above view has added that excessive coitus done by a woman having *Suksha* body or else a weak woman or at an early age with a man having big sized penis is also responsible for Various *Yonivyapada* by means of causing vitiation of *Vata*.

Accepting the abnormalities of *Artava* and *Bija* as well as *Daiva* as causative factors, both Acharya Vagbhatta have added the abnormal diet, having coitus in abnormal body postures, excessive coitus and use of any foreign body or substance for sexual pleasure are also responsible for the disease of reproductive tract i.e. *Yonivyapada*.

Vishista Nidana

Acharya Charaka and Vagabhatta have mentioned the specific *Nidana* (etiology) i.e., *Akalavahmanaya* or '*Akalevahna*' responsible for *Karnini yonivyapada*. So we can summarize etiological factor for *Karnini yonivyapada*.

1. *Mithyachara*
2. *Pradushta artava*
3. *Bija dosha*
4. *Daiva*
5. *Akalevahmanaya* or *Akalevahana*

Samprapti (Pathogenesis)

Acharya Charaka and Sushruta both are mentioned that *Yonivyapada* does not occur without vitiation of *Vata*.

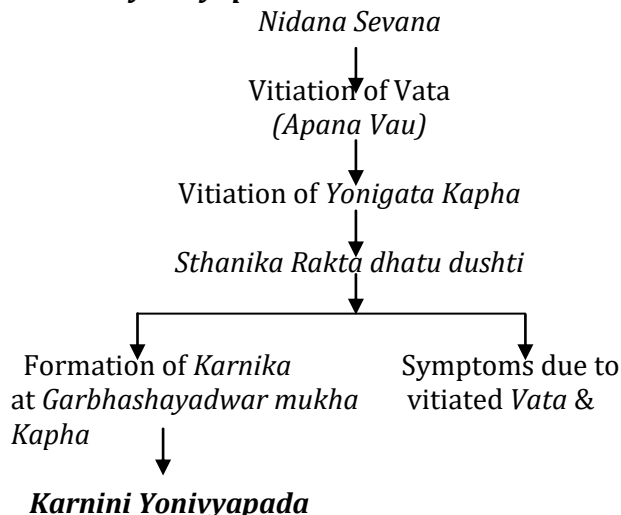
Acharya Charaka has clearly mentioned role of vitiated *Vata* and *Kapha* in *Samprapti* of *Karnini Yonivyapada* but Acharya Sushruta explained the pathogenesis in different manner, he describes that vitiated *Kapha* along with *Rakta* produces *Karnika* in *Yoni*.

While describing the general pathogenesis of *Yonivyapada* Acharya Sushruta has emphasized on the importance of the vitiated *Vata*, which ultimately leads to various *Yoniroga*, there he says that *Nidana sevan* leads to vitiation of *Vata* and this *Vata*, with holding *Pitta* and *Shleshma*, already vitiated due to their specific causes reaches to the *yon*i and produces different kinds of *Yoni roga*.

Acharya Charaka mentioned *Karnini yonivyapada* is *Vata-kaphaja doshaja* while classifying the twenty *Yonivyapada*. Sushruta describe *Karnini* in *Shleshmala yonivyapada*.

Thus from the above discussion it is clear that the causative *Doshas* in *Karnini yonivyapada* are vitiated *Vata* and *Kapha* and *Dushya* is *Rakta dhatu*.

Flow chart of *Samprapti* (pathogenesis) of *Karnini yonivyapada*



Samprapti Ghataka

- ◊ **Dosha** - *Vata (Apana), Kapha*
- ◊ **Dushya** - *Rakta Dhatu*
- ◊ **Adhithana** - *Garbhashaya dwarmukha (Cervix)*
- ◊ **Shrotas** - *Artav Vaha srotas.*
- ◊ **Shrotodushti** - *Sanga*
- ◊ **Vyadhi swabhava** - *Chirkari*
- ◊ **Sadhyaasadyata** - *Krichasadhya*

Rupa (Signs and symptoms) of Karnini Yonivyapada

The cardinal features of *Karnini yonivyapada* described in all the Ayurvedic classics, is '*Karnika*' developed at *Garbhashaya dwaramukha* (cervix) obstructing the passage of *Raja*.

Meaning of '*Karnika*' and related description is given previously.

This *Karnika* can be compared with nabothian follicle developed in follicular cervical erosion.

Karnika can also be correlated to the erosion on cervix which may be slightly raised above the level of squamous epithelium of vaginal portion of the cervix and is self and granular in appearance and when touched gives a grating sensation.

Further as the disease is the resultant of localized vitiation of *Vata* and *Kapha* in the region of *yonis*, so the symptoms produced due to these *Doshas* will also be found in this disease.

Acharya sushruta has clearly mentioned that the '*Shleshmala*' features will also be found associated in '*Karnini Yonivyapada*.'

Acharya Dalhana commentator of Sushruta says that due to vitiation of *Kapha* i.e. Unctuousness and itching are also present.

Symptoms due to vitiated Kapha

1. *Pandu Varna*
2. *Pichhila Yoni* means excessive mucoid discharge per vagina
3. *Kandu Yukta* i.e. Pruritis Vulvae
4. *Shitala Yoni* means wetness of vagina

Symptoms due to vitiation of Vata

1. Backache
2. Pain in lower abdomen
3. *Aayas* i.e. sickness feeling are also found in this disease

Modern Review**Cervical erosion****Etymology**

The word erosion is derived from Latin word "Erosion" ('E' means -off & 'Rode' means -

'worn off' denoting denudation of superficial epithelium) and from French word - "Eroder" which means 'to go away'. This leads to a wearing away or a state of being worn away, as by friction or pressure.

Definition

Clinically it is defined as the development of red velvety area on the portio vaginalis around the external os. Pathologically, cervical erosion is a condition in which the squamous epithelium of the ectocervix is replaced by columnar epithelium which is continuous with the endocervix.

Erosion of cervix received considerable attention in later half of 19th century.

Incidence

The incidence of the disease is increasing day by day as is evident from the data given below:

- Gray has mentioned the figure as 50.8%.
- One and a half decade later, Gray's incidence was raised by 5% (Shah, 1975).
- Profit and Sharma, H.S. (1993) mentioned the figure of incidence of Cervical erosion as 55%.
- More than three fourths of adult women suffer from this condition (Dawn, 1997).

Now days, it has been estimated that almost 80% of women of reproductive age group are suffering from this clinical entity and is contributing to the major part of all gynecological O.P.D.

An erosion / ectopy is not a static condition and the line of demarcation between the two types of epithelium moves to and from the external os. The functional zone is referred to as the 'transformation zone' of the squamocolumnar junction. When it is advancing towards the os, erosion is said to be 'healing'. Alternatively healing may also occur by squamous metaplasia of reserve cells in the endocervix.

Types

According to the process of formation and healing / re-epithelisation, the Cervical erosion can be classified as -

1. Congenital
2. Acquired
 - Simple Flat Erosion
 - Papillary Erosion
 - Follicular Cystic Erosion

Etiology

The causes which are held responsible for the Cervical erosion are broadly classified as.

- A. Congenital
- B. Acquired - Physiological
Pathological

Congenital

This is not a pathological state and is said to be found in at least one-third, some say all female babies at birth possibly because of exposure of maternal oestrogen in utero. The columnar epithelium of the cervical canal may extend to some extent over the vaginal portion of cervix. The condition persists for a few days after birth. On withdrawal of hormone, the erosion retrogresses. The ectopy tend to disappear during childhood only to reappear at or soon after puberty in one third of teenage girls. This again may be an oestrogen effect.

Acquired

Acquired causes can further be divided into 2 categories –

- ◆ Physiological
- ◆ Pathological

Physiological

In the adult as in the fetus and adolescent, Cervical erosion is determined by the amounts of oestrogen and progesterone in the circulation, the probable operative factor being oestrogen. During pregnancy and puerperium, sex hormone causes columnar epithelium overgrowth beyond external os, then retrogressing spontaneously during the subsequent 3 to 6 months. The finding of erosion a few weeks after delivery was formerly thought to be evidence of low grade puerperal infection and to require treatment. It is now generally recognized that it is a physiological reaction.

Pathological - Pathological causes are further divided into –

1. Hormonal
2. Infection
3. Environmental
4. Dietetic habits
5. Socioeconomic factors

1. Hormonal

- Sex hormonal hyperplasia – other than physiological conditions.
- Oral contraceptive hyperplasia –The taking of oestrogen – progesterone oral contraceptives often causes an erosion or makes one more obvious (therefore called 'pill ectopy'). Indeed these preparations sometimes result in gross proliferation of columnar epithelium of cervix, causing it move away from the external os.

2. Infection

An ectopy (erosion) of the cervix was once regarded as always being indicative of chronic cervicitis, and there are still some who surprisingly in view of the evidence hesitate to discard this concept. It was and still is postulated that the initial

infection, operating directly or by altering the vaginal pH and bathing the cervix in irritant discharge destroys the squamous epithelium around the external os leaving a denuded or potentially denuded area. At the same time it stimulates over activity of the endocervical epithelium which grows down and out to cover the raw area. This is pure theory and quite out of keeping with the known natural life history of cervical erosion. Moreover, it is ruled out by the fact that whenever an area of portio vaginalis is deliberately denuded, it is the squamous and not the columnar epithelium which grows in to cover it. Indeed, this is the basis of treating an ectopy (erosion) by destroying the columnar epithelium with a cauter, diathermy, cryotherapy or laser.

Cervical erosion may render the cervix more susceptible to infection with *N. gonorrhoea*, *C. trachomatis*, HPV or HIV⁹², because the columnar epithelium has less power of resistance to infection than the normal stratified squamous covering.

Herburt proposed infection theory divided into two parts:

A. Predisposing causes- It includes factors responsible for breaking down the normal barriers of infection via changes in the anatomical structure of the cervix, out flow of alkaline mucous, glycogen, menstrual flow, variations of hormones. Of these most imprints is change in the anatomical structure, which is mainly brought by trauma, excessive coitus, instrumental contraceptives (Cu.T, Loops), local chemicals, unhygienic irritants as douches, creams, jelly etc. Infections are most important cause according to Palak (1926) with incidence of 85%.

B. Precipitating factors- Bacterial infections mainly bacteria are Gonococci, Streptococci and Staphylococci work as precipitating factors. Works have been conducted recently to find the association of various organisms with cervical erosion. *Chlamydia trachomatis* was significantly associated with ectopy greater than 50% of total cervical area. Chronic cervicitis may present as erosion or one can say that during the process of healing chronic cervicitis leads to recurrent erosions of the cervix.

3. Environmental

It is sometimes said that changes in the pH of the vagina brought about by vaginitis, douching and chemical contraceptive can cause an ectopy but there is no convincing evidence in support of this.

4. Dietetic habits

Recently, it is also being held responsible for cervical metaplasia.

5. Socioeconomic Factors

In a clinical study a statistically significant association was found between lower socioeconomic status, early age at marriage and occurrence of cervical erosion ($p < 0.001$ & $p < 0.01$ respectively). The study concluded that socioeconomic factors such as illiteracy and low literacy status, lower socioeconomic status, early age at marriage and high parity are contributory for the occurrence of cervical erosion.

Pathology

1. Congenital erosion - This is not a pathological state and is said to be found in at least one-third, some say all female babies at birth possibly because of exposure of maternal oestrogen in utero. Towards the end of intrauterine life, columnar epithelium grows down from the cervical canal and in one third of all new born female children extent to some degree over the vaginal portion of the cervix. This condition persists for a few days until the level of oestrogen derived from the mother falls, and the congenital erosion heals spontaneously. Simple erosion is an oestrogen dependent condition, apart from birth it does not occur before puberty or in the postmenopausal state.

2. Acquired erosion - It was postulated by Robert Meyer (1910) that the interplay of columnar and squamous epithelium of the cervix leads to various types of erosion as follows:

a. Simple flat type- When squamocolumnar junction moves out wards, the columnar epithelium of endocervix continued on ectocervix and it ultimately replaces the squamous epithelium in single layer then it is called simple or flat type if erosion. During early stage of established cervicitis, pus and mucus are discharged from the cervical canal and bathe the cervix. The discharge is alkaline and tends to cause maceration of the squamous epithelium. As a result of (i) loosening by the underlying inflammation and (ii) constant bathing of the epithelium by irritating discharge - desquamation and shedding put of the epithelium around the external os occurs. In the process of healing, columnar epithelium from the cervical canal grows over and covers the denuded area, so that macroscopically the red area is covered by smooth glistening translucent epithelium. The affected area around the external os is simple flat erosion.

b. Papillary erosion- When replacement of squamous epithelium by columnar epithelium occurs and columnar epithelium some time proliferated and heaped up to form villous projections and forms papillary erosion. Hyperplasia of endocervical epithelium has been postulated to cause the papillary type of cervical erosion. Due to proliferation of the columnar epithelium, it gets folded and forms papillary projections on a granulation tissue base in chronic cervicitis. On the surface, pseudoglands or crypts form in between the papillae. One cause of this columnar epithelial hyperplasia is hormonal over activity. These papillary erosions are therefore commonly seen in pregnancy and they tend to regress spontaneously in the puerperium. During pregnancy, oestrogen is mainly responsible for causing erosion. Women who take hormonal contraceptives also show hyperplasia of the endocervical epithelium and papillary erosion on the cervix. These regress after the drug is discontinued.

c. Follicular Erosion - When replacement of squamous epithelium by columnar epithelium occurs and columnar epithelium arranged in hyperplastic manner and forming fold inwards this type of erosion known as follicular erosion.

Healing stage

It is considered that in the healing stage, the squamous epithelium grows towards the external os replacing the columnar epithelium which is made to atrophy and disappear. The squamous epithelium grows beneath the columnar epithelium until it reaches at or near to external os. The columnar epithelium gradually disintegrates. The mouth of the glands may be blocked with the regrown squamous epithelium and such glands may produce retention cyst like elevations on the surface of the portio vaginalis and these are called 'Nabothian follicles'.

Note

- Any type of erosion can become infected by micro organisms from the vagina, when chronic cervicitis coexists with erosion.
- The transformation zone in the reproductive phase of life is a dynamic area and changes in relation to endogenous and exogenous hormone levels. This explains why the cervical erosion is chiefly a disease during reproductive age and after menopause, it tends to retrogress spontaneously.
- Combination of all type of erosion can be seen in a single cervix with erosion.

Microscopic section

Histological picture may show the following –

1. Erosion area around the external os on the portio vaginalis shows the covering of columnar epithelium with the formation of new glands.
2. In follicular type, the surface is covered with stratified squamous epithelium with underlying retention cysts.
3. Beneath the epithelium the tissue often show round cell infiltration and glandular proliferation. Some assumes that these signs are indicative of chronic infection which precedes and causes the erosion. Any inflammatory process however is more likely to be secondary, the columnar epithelium having less power of resistance to infection than the normal stratified squamous covering.
4. In follicular stage, histological picture may be mistaken for carcinoma.

Clinical Features

Symptoms

The lesion may be asymptomatic. However quite often the following symptoms are present.

1. Vaginal discharge – Profuse mucoid discharge per vagina is quite often the presenting feature due to which the patient lands up in gynecological OPD. The discharge may vary in character. It may be excessively mucoid in character due to the overgrowth or overactive cervical crypts (e.g. in hyperplastic erosion). Sometimes it is mucopurulent, offensive and irritant in the presence of infection (in inflammatory erosion). It may be even blood stained due to premenstrual congestion.
2. Contact bleeding –The epithelial area is fragile and sometimes it may bleeds on coitus. Post coital bleeding in vascular erosion is seldom a symptom in non pregnant woman, this is the symptom of cervical neoplasia rather than that of cervical erosion. But contact bleeding may be quite common during pregnancy, because in that condition erosion becomes highly vascular and bleeds easily. Contact bleeding is also associated with oral contraceptive pill use.
3. Low backache
4. Pelvic pain
5. Deep dyspareunia
6. Infertility
7. Chronic ill health and metastatic infection – arthritis, muscular pains.
8. There may be frequency of micturition and dysuria perhaps due to spread of infection around the bladder wall.

9. Pruritis vulva does not ordinarily be the symptom but may be present in profuse mucous discharge.
10. Psychological upsets due to persistent vaginal discharge since it is believed by lay public that white discharge is white blood. Consequently she develops palpitation and sense of unwell.

Signs

1. General health may be below normal, there may be slight anaemia.
2. Internal examination (Per speculum) - It is a diagnostic procedure. It reveals-
 - There is a bright red area surrounding and extending beyond the external os in the ectocervix. The outer edge is clearly demarcated. On the other hand hyperaemia resulting from acute cervicitis fades gradually into the normal tissue. The lesion may be smooth or having small papillary folds.
 - It is not tender unless complicated by infection.
 - When associated with chronic cervicitis, the cervix feels fibrosed, bulky with nabothian follicles around the area of erosion.
 - Mucoid discharge may be seen emanating through the os and around the erosion.
 - It generally does not bleed on touch. On rubbing with a gauze piece, there may be multiple pinpoint oozing spots (sharp bleeding in isolated spots in carcinoma).
 - The feel is granular giving rise to a grating sensation when stroked with the tip of finger. The impression is similar to that provoked by attempting to smooth velvet against its pile.

Diagnosis

- **Per speculum** - Speculum examination of the cervix is the diagnostic procedure.
- **Pap smear**- In every case, Pap stain cytological examination from cervical scrape and vaginal smear should be performed to screen out dysplasia, carcinoma in situ and early carcinoma. In all women with abnormal Pap test showing mild dysplasias, it is important to treat any inflammatory pathology and repeat the Pap test.
- **Colposcopy and Biopsy**- In lesions with suspicious or cytological positive smear cases colposcopy and then cervical biopsy must be performed for histological diagnosis.

Complications

1. Spread of infection to cause bladder and urinary tract infection, arthritis.
2. Chronic invalidism: It however remains unproven that cervical erosion predisposes

cervical carcinoma. Mild dysplasia is often seen with inflammatory conditions like trichomoniasis and HPV (Human Papilloma Virus), and is reversible following treatment, whereas the severer varieties progress to invasive cancer in about 10 to 30 % of cases in 5 to 10 years time.

3. Infertility

Differential Diagnosis

The diagnosis of cervical erosion is often confused with –

1. Ectropian

Bilateral vertical laceration of cervix disrupts the connective tissue and circular fibromuscular fibers, leaving the longitudinal fibers of the external cervical muscle free to act unopposed. The lips of the cervix are curled back to upwards and outwards to expose the endocervix. The red looking endocervix then becomes exposed, so the condition is confused with erosion. They may be apparent when the lips of the cervix are stretched by the bivalve speculum.

2. Early carcinoma

It is indurate, friable and usually ulcerated which bleeds to touch. Confirmation is by biopsy, if necessary following Schiller's iodine application or colposcopy directed.

3. Primary sore / Syphilitic ulcer

There is denudation of the epithelium without excavation of the cervical tissue. The ulcer has a punched out appearance. Smear examination under dark ground illumination microscopy, identifies the treponemata.

4. Tubercular ulcer

This is indurate ulcer with caseation at the base. Biopsy confirms the diagnosis.

DISCUSSION

In Ayurvedic Classics the Ayurvedic disease review including description about *Yoni, Garbhashaya*, references related to cervix in Ayurvedic literature, Ayurvedic disease review, correlation between *Karnini yonivyapad* and cervical erosion description. Modern review includes anatomy of female reproductive organs and modern disease review. In both Ayurvedic review and Modern Review there is much similarity in the *Karnini Yonivyapad* and Cervical erosion

CONCLUSION

Hence it can be concluded that the disease *Karnini yonivyapad* described in Ayurvedic classics can be considered as one of the clinical presentation of cervical erosion on the basis of above given Ayurvedic and Modern review.

REFERENCES

1. Ayurveda Sara Sangraha; Published by Shri Baidyanath Ayurveda Bhawan Pvt. Ltd., Calcutta; Edition 1999.
2. Bangasena; Bangasena Samhita (Chikitsa Sara Sangraha) with Hindi Commentary of Rajiva Kumara Raya; Prachya Prakashan, Varanasi; 1st Edition 1983.
3. Bhagel M. S.; Researches in Ayurveda; Mridu Ayurvedic Publications & Sales, Jamnagar, 1st Edition – 2005.
4. Bhatla Neerja; Jeffcoate's Principles of Gynaecology; Arnold Publications; 6th International Edition
5. Bhatta Krishnaram; Siddhabhesajamanimala; Edited with Vaishwanara Hindi commentary; Chowkhamba Krishnadas Academy, Varanasi, 3rd Edition Reprint -2003.
6. Bhela Samhita by Girijadualu Vidyabhawan, Varanasi, First Edition 1959.
7. Cotran S. Ramzi, Kumar Vinay, Robbins L. Stanley; Robbins Pathologic Basis of Disease, W. B. Saunders Company; 5th Edition -1994.
8. Desai Ranjit Rai; Nidana Chikitsa Hastamalaka; Sri Baidhyanath Ayurveda Bhavana Limited, Calcutta, Vol. 1,1st Edition- 1978.
9. Desai Ranjit Rai; Nidana Chikitsa Hastamalaka; Sri Baidhyanath Ayurveda Bhavana Limited, Calcutta, Vol. 1,1st Edition- 1978.
10. Gupta Atrideva, Ashtangahridayam of Vagbhatta, Edited with Vidyotini Hindi commentary;Chaukhambha Prakashan, Edition Reprint -2008.
11. Harrison's Principle of Internal Medicine; Mc. Grew Hill Companies; 16th International Edition – 2008.
12. Howkins And Bourne; Shaw's Textbook of Gynaecology; Elsevier Publication; 14th Edition – 2008.
13. Howkins John, Stallworthy John; Bonney's Gynaecological Surgery; CBS Publishers and Distributors;1st Indian Edition.
14. Kashyapa Samhita with Vidyotini Hindi Commentary by Sri Satyapala Bhisgacharya, Chaukhambha Sanskrit Sansthan, Varanasi, 2004.
15. Shastri Ambikadutta; Sushruta Samhita, Hindi Commentary; Chaukhamba Sanskrit Sansthan, Varanasi, Edition Reprint- 2007.
16. Shastri Kashinatha & Chaturvedi G.N.,Charaka Samhita, Vidyotini Hindi commentary,

- Chaukhamba Bharati Academy, Varanasi, Edition Reprint -2003.
17. Shastri Laxmipati; Yogaratnakara; Chaukhambha Sanskrit Series Office, Varanasi; Edition 1973.
18. Shaw W Robert, Soutter Patrick W. Stanton L. Stuart; Gynaecology; Churchill Livingstone, Elsevier Science Limited Publication, 3rd Edition- 2003.
19. Tewari Premvati; Ayurvediya Prasuti Tantra Evam Striroga; Chaukhambha Orientalia, Varanasi; 2nd Edition; Reprint 2007.
20. Tortora J. Gerard, Bryan Derrickson; Principles of Anatomy and Physiology; John Wiley & Sons Inc.; 11th Edition 2007.

Cite this article as:

Sonika Pal, Chandra Prakash. A Critical Review on Karnini Yonivyapad w.s.r. to Cervical Erosion. AYUSHDHARA, 2017;4(6):1478-1485.

Source of support: Nil, Conflict of interest: None Declared

Disclaimer: AYUSHDHARA is solely owned by Mahadev Publications - dedicated to publish quality research, while every effort has been taken to verify the accuracy of the content published in our Journal. AYUSHDHARA cannot accept any responsibility or liability for the articles content which are published. The views expressed in articles by our contributing authors are not necessarily those of AYUSHDHARA editor or editorial board members.

