



Case Study

A CASE REPORT ON GUGGULU BASED KSHARSUTRA ALONG WITH SAPTAVINSHATI GUGGULU IN TREATMENT OF BHAGANDARA (FISTULA-IN-ANO)

Suman Yadav^{1*}, Ashutosh Kumar Yadav², Anand puri³

¹Associate Professor & H.O.D., ³P.G. Scholar, Department of Shalya Tantra, Government PG Ayurvedic College, Sampurnanand Sanskrit University, Varanasi, UP, India.

²Associate Professor, Department of Rachana Sharir, Government PG Ayurvedic College, Sampurnanand Sanskrit University, Varanasi, UP, India.

KEYWORDS: *Bhagandar, Bhaga, Basti, Guda, Kshar sutra, Pidika, Saptavinshati gugglu.*

ABSTRACT

Bhagandara is one of the commonest diseases which occur in anorectal region. *Acharya Sushruta* had described this disease in *Ashtamahagada* that means disease difficult to cure. It starts as deep rooted *Pidika* around the *Guda* within two *Angula* or finger circumference and form into a track with an external opening in the skin of perianal region and an internal opening in the mucosa of anal canal or rectum lined by unhealthy granulation tissue and fibrous tissue which in modern science can be correlated to *Fistula-in-ano*. As the recurrence rate of *fistula in ano* is high after modern treatment. To overcome these difficulties, the concept of *Ksharsutra* mentioned in the classics is very beneficial from the treatment point of view. So, the *Guggulu (Commiphora mukul)* based *Ksharsutra* therapy along with oral Ayurvedic formulations is taken to prove its efficacy in treating *Bhagandara*. Here a case report of a 32 year old, male patient having history of *Bhagandara (Fistula-in-ano)* since last 2 years is discussed. He had complaints of left gluteal swelling, pain, pus discharge from perianal region and itching around anal region. For which he took allopathic treatment and got no relief, finally patient came to our hospital for better Ayurvedic management. He was treated with *Guggulu* based *Ksharsutra* therapy along with oral medication of *Saptavinshati Gugglu vati* 500 mg with water twice daily. Lastly, he got treated in 60 days and follow up of the patient was maintained up to 6 months where no complication was reported. It was proved that *Ksharsutra* application in combination with oral Ayurvedic medication worked effectively. This case report will help and enlighten the budding young scholars working in this area.

*Address for correspondence

Dr. Suman Yadav

Associate Professor & H.O.D., P G
Department of Shalya Tantra,
Government Ayurvedic College,
Sampurnanand Sanskrit University,
Varanasi, UP, India

Email:

yadavsuman2073@rediffmail.com

Phone: 09451965767

INTRODUCTION

Acharya Sushruta had described this disease in *Ashtamahagada*.^[1] The disease *Bhagandara* is defined as deep rooted *Pidika*^[2] around the *Guda* within two *Angula*/finger circumference. *Bhagandara (Fistula-in-ano)* is a condition which has been recognized as a difficult surgical disease in the ancient and modern medical sciences of the world. It is the recurrent nature of this disease which makes it more and more difficult for treatment. It has been categorized as a surgical condition and almost all the surgeons starting from

Sushruta (about 1500 B.C- India) to Hippocrates (450 B.C.) and also by the present day modern surgeon face challenges due to its notorious nature, which increases the level of difficulty.

The literally meaning of *Bhagandara* is *daran-* tear/ split around the *Bhaga, Guda* and *Basti*. When there is *Pidika* around the *Guda pradesh* then it is called *Bhagandara pidika* and when this *Pidika* get suppurates and burst then it is called *Bhagandara*. In modern medical science the *Bhagandara* resemble with *Fistula in ano*.

Bhagandara^[3] is not a life threatening disease but disturbing the quality of life significantly because it causes discomfort along with pain and pus discharge from anal region. Treatment of *Bhagandara* is scientifically described in *Samhita*; also *Acharya's* instructed to avoid the causative factors of disease. This is the region which is more prone to infection having direct contact with stool and thus any disease originated from this take more time to heal. The techniques for treatment of fistula in ano generally used by modern surgeons are fistulectomy, fistulotomy, Video Assessed Anal Fistula Treatment, Ligation of inter sphincteric fistula treatment etc, which causes incontinence by damaging anal sphincter. So there is strong need of a treatment which does not cause incontinence and will not hamper the daily routine of the patient. The *Ksharsutra*^[4] application along with oral medicine is better treatment for such fistula in ano and to prove this, a case report is discussed here in which the *Saptavinshati Guggulu*^[5] is advised orally along with *Ksharsutra* therapy to see its combined effect.

Case Report

A 32 year old male patient who is policeman came to our hospital with chief complaints of

1. Left gluteal swelling which is prominent around perianal region since 1 month
2. Local pain since 20 days
3. Pus discharge since 20 days
4. Itching since 20 days
5. H/o- Fistula in ano since last 2 years

History of present illness: According to the patient he was well before 2 years and after that since 1 month, he developed swelling on left gluteal fold which is more prominent around peri-anal region for which he took modern medicine and got no relief. He is complaining of local pain since 20 days and peri anal swelling which spontaneously burst open with pus discharge oozing. Also, the pus discharge is coming off and on from the wound which is wetting his undergarments. So since last 20 days he is suffering from pus discharge along with itching in that region, for which he finally came to our hospital for better Ayurvedic management.

History of past illness - No H/o D.M, T.B, Asthma, Epilepsy, HTN.

Personal History

Appetite- Average
Food- Mixed (spicy)
Bowel- constipated

Addiction- Tobacco, Pan chewing

Micturation – Frequency 7-8 times in 24 hrs, flow-normal

Sleep- Improper, 6-7 hrs/day (disturbed at the time of pain)

MATERIAL AND METHOD

This is a single case report in which patient reported to Shalya Tantra OPD of Govt. P.G. Ayurvedic College & Hospital, Chaukaghat, Varanasi, UP. Informed consent of the patient was taken. Then the patient was planned for treatment with *Guggulu* based *Ksharsutra* therapy along with *Saptavinshati Guggulu* oral administration. The *Guggulu* based *Ksharsutra* was prepared in our departmental laboratory.

OPERATIVE PROCEDURE

Operative procedure was performed under local anesthesia using aseptic measures. After assessment of the tract manually using copious amount of 2% xylocaine jelly followed by probing through metallic malleable probe and finally primary threading was done by ligation of both ends of *Ksharsutra* tied together. Latter on *Guggulu* based *Ksharsutra* was changed once on weekly basis till the end of the treatment.

Management

Patient was treated with *Saptavinshati Guggulu* 500mg BD orally with water. During this treatment he was taking *Saptavinshati Guggulu vati* daily orally as advised until got completely treated. He was instructed for hot sitz bath up to 10 minutes after defecation. Patient was also advocated regarding *Pathya Apathya* (Do's and Dont's).

Assessment criteria

1. Pain- assessment was done depending on use of oral medicine.
2. Itching- assessment was done depending on use of medicine.
3. Pus discharge- depending on number of gauge used.

OBSERVATION

The patient was observed on regular basis before, during and after treatment. All the observation about the progress of treatment was recorded. The fistulous tract healed completely in 8 week of treatment. The patient can do all his routine work; also no recurrence of symptom was noted up to 6 months of follow up.

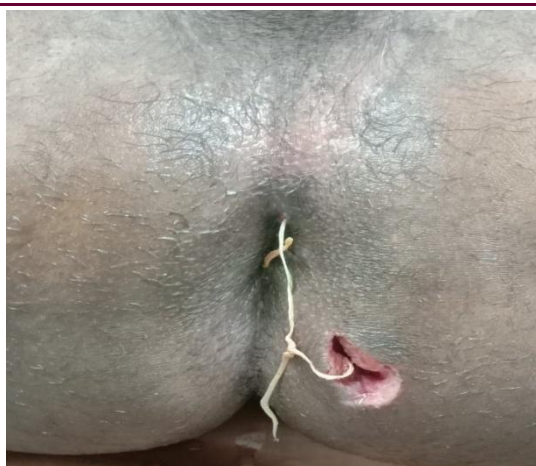


Fig 1 During treatment

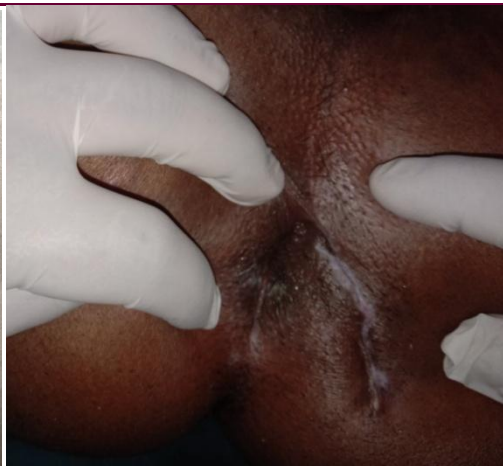

Fig 2 After treatment

Table 1: Observations of Pain during the treatment

Day	No pain (-)	Mild pain (+) rarely needs oral medicine	Moderate pain (++) needs less frequent oral medicine	Severe pain (+++) needs very frequent oral medicine
Day 1	-	-	-	+++
Day 2	-	-	-	+++
Day 3	-	-	-	+++
Day 7	-	-	++	-
Day 14	-	+	-	-
Day 28	+	-	-	-
Day 60	-	-	-	-

Table 2: Observations of Itching during the treatment

Day	No itching (-)	Mild itching (+) rarely needs medicine	Moderate itching (++) relief with medicine	Severe itching (+++) no relief with medicine
Day 1	-	-	-	+++
Day 2	-	-	++	-
Day 3	-	-	++	-
Day 7	-	++	-	-
Day 14	+	-	-	-
Day 28	+	-	-	-
Day 60	-	-	-	-

Table 3: Observations of Discharge during the treatment

Day	No discharge (-)	Mild discharge(+) used 1/2 gauze of 2cm x 2 cm	Moderate discharge (++) used 3/4 gauze of 2cm x 2cm	Severe discharge (+++) used more than 4 gauze of 2 cm x 2 cm
Day 1	-	-	-	+++
Day 2	-	-	-	+++
Day 3	-	-	-	+++
Day 7	-	-	++	-
Day 14	-	+	-	-
Day 28	+	-	-	-
Day 60	-	-	-	-

DISCUSSION

The reference of *Ksharsutra* is mentioned in the ancient classics. For *Bhagandara* (fistula-in-ano) treatment, the *Ksharsutra* therapy is the best popular method till now. In this treatment *Guggulu* based *Ksharsutra* was inserted through the external opening passing through the tract and ending at internal opening, now both ends of the thread are tied outside.^[6] This medicated thread performs

function of cutting of fistulous tract, debridement of unhealthy tissue and healing of fistulous tract leaving behind scar formation.

On other hand the *Saptavinshati Guggulu* which is taken orally also enhances the healing, as this oral medication has Anti-inflammatory, Antibacterial, Analgesic and Antioxidant property.

Patient walks and sits smoothly after 2 weeks of treatment and also resumed his routine duty. The whole course of treatment took 60 days for full recovery.

The *Saptavinshati Guggulu* have 28 contents in which maximum content are herbs such as *Amalaki*, *Vibhitak*, *Haritaki*, *Daruharidra*, *Vidang*, *Shunthi*, *Pippali*, *Maricha*, and *Guggulu* etc. All these herbs are used in India medicinally for the treatment of variety of diseases. The mechanism of action of *Saptavinshati Guggulu* is based on the presence of alkaloids, active principles and other chemical constituents. Some of the important constituents which promote the wound cleaning and healing properties of this oral medication are discussed here.

Amalaki having Tannins, Phyllembin performs Anti-bacterial and Anti-viral activity and also works as to restore a healthy endothelial lining, whereas Embelin has Anti-oxidant, Anti-inflammatory and tissue rejuvenating property.

Vibhitak having Ellagic acid, Gallic acid, Manitol which has Anti-secretory, Analgesic, Anti-spasmodic, Anti-microbial, Wound healing, Anti-pyretic and Immunological property.

Haritaki having hydrolysable tannins like Gallic acid and Ellagic acid. *Haritaki* has wound healing, Anti-microbial, Anti-bacterial, Anti-fungal and Anti-oxidant property.

Guduchi having Berberin, Palmatine, Magnoflorine, Tinosporin which act as Immuno-modulator, NSAID and Anti-oxidant property.

Vidang having Embelic, Tannin, Sitosterol and Benzofuron which works as Anti-biotic, Anti-bacterial and Anti-oxidant.

Haridra having Curcumin, Phytophenol works as Anti-inflammatory, Anti-oxidant, Wound healing and Anti-microbial property.

Daruharidra having Berberin which possesses Anti-bacterial, Anti-fungal, Anti-oxidant and Anti-inflammatory property.

Guggulu contains diterpenoids, triterpenoids, steroids, ligans, and Allylcembrol which has Fibrinolytic activity, Anti-inflammatory, Anti-oxidant, Cytotoxic, Antimicrobial, Antiseptic and Wound healing property.

Because of having all these properties *Saptavinshati Guggulu* is widely used in post-operative period for the management of pain and promotes faster wound healing.

CONCLUSION

The most scientific description of *Bhagandara* is given in *Sushruta samhita*. For treatment of *Bhagandara*, *Ksharsutra* is the best treatment modality till now. In this case report, when we used *Guggulu* based *Ksharsutra* application along with *Saptavinshati Guggulu* orally, it was observed that the time taken for complete healing of the fistulous tract was reduced. This Ayurvedic, parasurgical procedure along with oral medicine has an advantage over other modalities of treating *Bhagandara*. This scientific approach in the management of *Bhagandara* will provide great help to the patients.

REFERENCES

1. Sushruta Samhita, Ayurveda – Tattva-sandipika, hindi commentary by Acharya Kaviraja Ambikadutta Shastri, Chaukhambha Sanskrita Sanshtan, Varanasi, reprint 2014, Sutrasthana, 33/4, p. 163.
2. Sushruta Samhita; Dalhana commentary by Yadavji Trikamji, Chaukhambha Surabharati Prakashana, Varanasi, edi. 2008, Nidanasthana 4/12, p. 280.
3. Sushruta Samhita, Ayurveda– Tattva- sandipika, hindi commentary by Acharya Kaviraja Ambikadutta Shastri, Chaukhambha Sanskrita Sansthan, Varanasi, reprint 2014, Chikitsasthana, chapter 8, p. 57-62.
4. Chakradatta, Shree Cakrapani dutta by Shastri R, Chaukhambha surbharati prakashan; Varanasi, Arsha Chikitsa 5/148; 2006, p. 44.
5. Bhaisajya Ratnavali, Vidyotini hindi commentary by Kaviraj Ambikadutta Shastri, Chaukhambha Prakashan, Varanasi, Bhagandar chikitsa/ 29-34, p.871.
6. Kumar Anil *et al*, The easiest way to insert Ksharsutra with the help of an infant feeding tube instead of a metallic probe Internal. Journal of Surgery published on 21 June 2017. Indian J Surg.2017 Aug; 79(4): 371-373.

Cite this article as:

Suman Yadav, Ashutosh Kumar Yadav, Anand puri. A Case Report on Guggulu Based Ksharsutra Along With Saptavinshati Guggulu in Treatment of Bhagandara (Fistula-In-Ano). AYUSHDHARA, 2020;7(3):2711-2714.

Source of support: Nil, Conflict of interest: None Declared

Disclaimer: AYUSHDHARA is solely owned by Mahadev Publications - A non-profit publications, dedicated to publish quality research, while every effort has been taken to verify the accuracy of the content published in our Journal. AYUSHDHARA cannot accept any responsibility or liability for the articles content which are published. The views expressed in articles by our contributing authors are not necessarily those of AYUSHDHARA editor or editorial board members.