



## Case Study

### MANAGEMENT OF ASCITES (*JALODARA*) THROUGH ANCIENT SYSTEM OF MEDICINE- A CASE REPORT

S.R.Tarapore<sup>1\*</sup>, R.A. Shaha<sup>2</sup>, J.D.Khot<sup>1</sup>

<sup>1</sup>Assistant Professor, <sup>2</sup>P.G. Scholar, Dept. of Kayachikitsa Department of SGR Ayurved College, Samrat Chowk, Solapur, Maharashtra, India.

**KEYWORDS:** Ascites, *Jalodara*, *Shodhana Aushadhis*, *Shamana Aushadhis*.

#### ABSTRACT

Ascites is a pathologic condition and accumulation of free fluid where fluid accumulates in the peritoneal cavity commonly observed in decompensated cirrhotic states. Symptoms may include increased abdominal size, increased weight, abdominal discomfort and shortness of breath. There is no specific treatment where ascetic pathology will cure completely. By contemporary science where patient gets temporary relief and symptomatic relief from their complaints. But after Paracentesis again fluid gets collected in the peritoneal cavity. In such cases, *Ayurvedic* treatment gives satisfactory relief from complaints along with hidden pathology. In this present article above mentioned ascites i.e., nothing but one among the liver pathology attempted to correlate with *Jalodara* which is very well mentioned in classics. A 45 years old male patient came to our Medicine outpatient department having complaints of *Kshudhamandya* (Loss of appetite), *Annanabhilasha* (Anorexia), *Ubhaya Paada Shotha* (Oedema), *Netra Pitata* (Icterus), *Udara Vridhdhi* (fullness in flanks). Subject had treated thirteen days by *Shodhana Aushadhis*, *Shamana Aushadhis* also by diet restriction.

#### \*Address for correspondence

##### Dr. S.R.Tarapore

Assistant Professor,  
Dept. of Kayachikitsa  
Department of SGR Ayurved  
College, Samrat Chowk, Solapur,  
Maharashtra, India.  
Email:  
[shrutitarapore24@gmail.com](mailto:shrutitarapore24@gmail.com)

#### INTRODUCTION

The term "ascites" is derived from the Greek term "*askos*" in reference to its similar appearance to a wine bag or sac<sup>[1]</sup>. Ascites is one of the most frequent complication to cirrhosis occurring in approximately 60% of patients within 10 years of poor prognosis. The development of ascites in the setting of cirrhosis represent a landmark in the natural history of cirrhosis, predicting a poor prognosis with 50% mortality within 3 years<sup>[2]</sup>. The principles behind treatment of ascites include diuretics, paracentesis, insertion of a trans-jugular intrahepatic portosystemic shunt (TIPS)<sup>[3]</sup>, as well as managing complications to ascites such as spontaneous bacterial peritonitis (SBP)<sup>[3]</sup>. By this treatment, only fluid amount decreases but chances of reoccurrence of fluid are more. So, here is attempt to present single case study. Ascites resembles *Udararoga* in *Ayurveda*<sup>[4]</sup>. *Vata* is main culprit for *Udararoga*<sup>[5]</sup>. Our body needs fuel in the form of food (*Aahara*), but it is not absorbed as it is, first it has to go through whole process of digestion

with action of *Agni*.<sup>[6,7]</sup> In *Udara*, involvement of *Tridoshas* are mentioned<sup>[8]</sup>. Among *Tridosha*, the *Prakupita Vata* gets accumulated in *Udara* between *Twaka* and *Mamsa* leading to *Shotha*, which is known as *Jalodara*<sup>[9]</sup>. *Mandagni* is one of the causes for *Jalodara* along with *Vata*<sup>[10]</sup>. There are multiple factors involved in this causation as mentioned above. To get relief, proper treatment and diet is required. For this, salt and water restriction is mainly focused. Patient is only allowed to consume *Godugdha*<sup>[11]</sup> as complete diet. By this treatment plan, *Samprapti Vighntana* has occurred.

#### Patient information

A 45 year old Male subject came to our hospital of *Kayachikitsa* outpatient department. He had complaints of *Kshudhamandya* (Loss of appetite), *Anannabhilasha* (Anorexia) since 2 months followed by *Udara Vridhdhi* (fullness in flanks), *Ubhaya Paada Shotha* (*Nonnmati*- pitting oedema), *Netra Pitata* (Icterus) since 1 month, along with that, he had associated complaints i.e.,

*Alpa Mutrapravritti* (urine incontinence) (*Sadaha*), *Aayasena Shwaskashata* (Dyspnea), *Kandu* (Itching) and *Daha* on *Udarpradesha*. Severity gets increased during 8 days for those associated symptoms. For above mentioned complaints, he consulted a physician. He was diagnosed as Ascites. For this, he had undergone Paracentesis 20 days back before the approaching us. Around 3 litres fluid was removed in one setting. Outside prognosis was not so good, so, subject again faced same problem, so he approached for special *Ayurvedic* Treatment.

### Clinical findings and diagnostic assessments

On OPD base, the patient was undergone below examination. By this, we could conclude as there was accumulation of fluid.

### Inspection

The skin was tightened and shiny. The umbilicus was everted. There was no muscle wasting. Spider Navae sign was absent. By this observations, there is possibility of accumulated fluid in the peritoneal cavity.

### Palpation

Superficially tenderness was present so, liver and spleen were not palpable by dipping method.

### Percussion

Fluid Thrill Test, Shifting dullness and Horse shoe sign were positive.

### Timeline

Subject had undergone with the process of Paracentesis 20 days before the admission to our hospital. In one setting around 3 litres of fluid was removed. He was complaining about *Kshudhamandya* (Loss of appetite), *Anannabhilasha* (Anorexia) from 2 months followed by *Udara Vridhdhi* (Fullness in flanks), *Ubhaya Paada Shotha* (Nonnamiti- Pitting oedema), *Netra Pitata* (Icterus) from 1 month. Severity of *Alpa Mutrapravritti* (Urine incontinence) (*Sadaha*), *Aayasena Shwaskashata* (Dyspnea), *Udarpradeshi Kandu* (Itching) and *Daha* increased from last 8 days. Also, he had history of Jaundice which was treated by physician. He faced same complaints again as mentioned above due to his continuation of addiction. Patient had shown signs of tachycardia (90min), Oliguria, Pallor and Icterus. RS- decreased air entry bilateral lower zone, Tremors were absent and Pitting oedema was present B/L LL. Investigation was done.

|                        | 17/12/2019                | 28/12/2019             |
|------------------------|---------------------------|------------------------|
| Hb                     | 8.3 gm/dl                 | 10.5gm/dl              |
| WBC                    | 9400/mm <sup>3</sup>      | 8100/mm <sup>3</sup>   |
| Platelet               | 364000/mm <sup>3</sup>    | 408000/mm <sup>3</sup> |
| Bilirubin(T)           | 1.56mg/dl                 | 1.36mg/dl              |
| (D)                    | 0.40gm/dl                 | 0.5mg/dl               |
| (ID)                   | 1.16mg/dl                 | 0.86mg/dl              |
| SGPT                   | 206U/L                    | 94U/L                  |
| SGOT                   | 181U/L                    | 87U/L                  |
| Alkaline Phosphate     | 185U/L                    | 192IU/L                |
| BSL(R)                 | 82mg/dl                   |                        |
| Sr. Creatinine         | 0.7mg/dl                  |                        |
| B.T.                   | 1min.57sec.               |                        |
| C.T.                   | 4 min.50sec.              |                        |
| Urine (R)              | Bile Salt/pigment-Present |                        |
| Total Protein          | 7.9gm/dl                  |                        |
| Australia Antigen Test | Negative                  |                        |

### USG (Abdomen) 5/12/2019

Mild hepatomegaly with coarse echo texture of liver parenchyma mild ascites.

### USG (Abdomen and Pelvis) 23/12/2019

Moderate hepatomegaly with mild splenomegaly with changes of liver cirrhosis with portal hypertension with gross ascites and mild

bilateral pleural effusion, No E/O focal mass / Neoplasmin liver/ Spleen/ Pancreas, No E/O GB Calculi/ GB mass seen.

### Materials and Methods

### Therapeutic Intervention

As he was diagnosed with *Jalodara* in which *Tridoshas* are involved but showing different signs

and symptoms mainly *Vata* and *Kapha* are culprited. He was admitted in hospital, follow up was taken daily and treated with *Deepana- Pachana*

*Aushadhis, Nitya Virechana, Shamana Aushadhis, Arka and Eranda Patra Bandhana.*

### **Shamana Aushadhis**

| Date           | Treatment  | Matra (Dose) | Kala                   | Anupana            |
|----------------|--|--------------|------------------------|--------------------|
| 18/12 to 20/12 | <i>Pachak Vati</i>   | 1 TDS        | <i>Vyanoudana Kala</i> | <i>Koshna Jala</i> |
| 19/12/2019     | <i>Laghu Sutashekhhar</i>  | 500 mg       | <i>Vyanoudana Kala</i> | <i>Koshna Jala</i> |
| 21/12 to 30/12 | <i>Arogyavardhini</i><br><i>Daruharidra</i><br><i>Sharpunkha</i> | Each 500 mg  | <i>Vyanoudana Kala</i> | <i>Koshna Jala</i> |
| 21/12 to 30/12 | <i>Avipattikar Churna</i>  | 2 gm         | <i>Nishakali</i>       | <i>Koshna Jala</i> |
| 22/12/2019     | <i>Shankh Vati</i>   | 250 mg       | <i>Vyanoudana Kala</i> | <i>Koshna Jala</i> |
| 23/12 to 30/12 | <i>Kamdudha Rasa</i>   | 1 gm         | <i>Vyanoudana Kala</i> | <i>Koshna Jala</i> |
| 24/12 to 30/12 | <i>Guduchyadi Churna</i>   | 10 gm        | <i>Vyanoudana Kala</i> | <i>Koshna Jala</i> |
| 26/12 to 30/12 | <i>Hingavashtaka Churna</i>                                      | 125 mg       | <i>Muhurmuhu</i>       | <i>Mudga Yusha</i> |

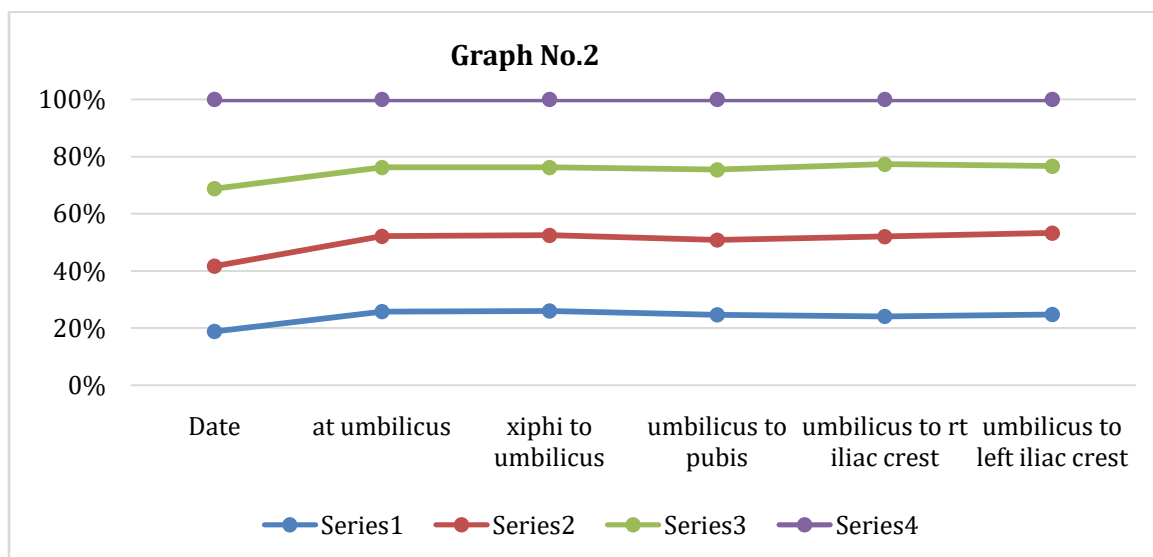
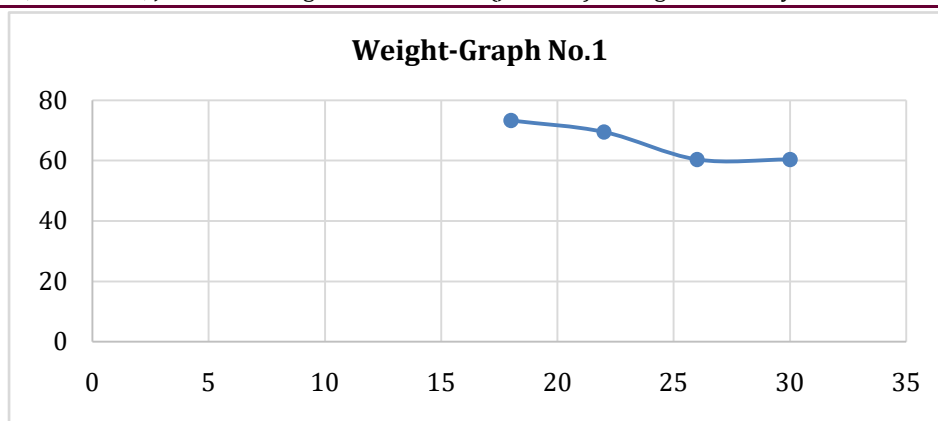
### **Panchakarma treatment**

|                          |                              |          |                |                     |
|--------------------------|------------------------------|----------|----------------|---------------------|
| 19/12 to 21/12           | <i>Haritaki Churna</i>       | 5 gm     | <i>Abhakta</i> | <i>Koshna Dudha</i> |
| 22/12 to 23/12           | <i>Haritaki Churna</i>       | 3 gm     | <i>Abhakta</i> | <i>Koshna Dudha</i> |
| 24/12 to 25/12           | <i>Haritaki Churna</i>       | 5 gm     | <i>Abhakta</i> | <i>Koshna Dudha</i> |
| 26/12 to 27/12           | <i>Haritaki Churna</i>       | 3 gm     | <i>Abhakta</i> | <i>Koshna Dudha</i> |
| 28/12 to 29/12           | <i>Haritaki Churna</i>       | 5 gm     | <i>Abhakta</i> | <i>Koshna Dudha</i> |
| Date                     | Treatment                    | Duration |                |                     |
| 27/12/2019 to 29/12/2019 | <i>Arka Patra Bandhana</i>   | 2 hrs.   |                |                     |
| 30/12/2019               | <i>Eranda Patra Bandhana</i> | 2 hrs.   |                |                     |

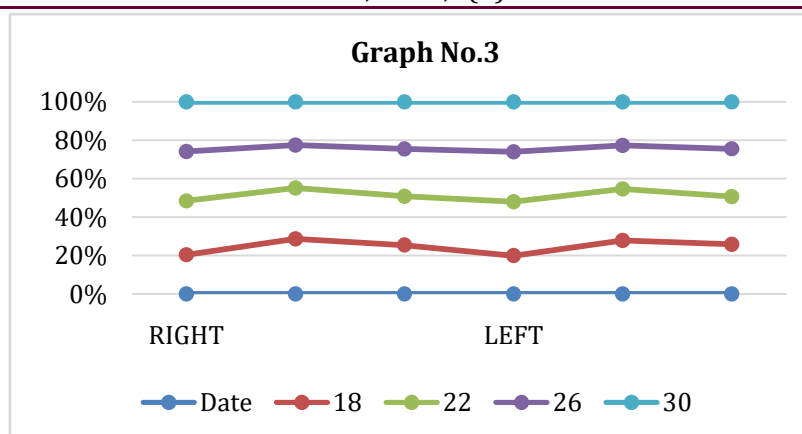
### **Follow up and outcomes**

He was treated from 18 Dec.2019 to 30 Dec. 2019 assessed by weight, Abdominal Girth, measurement from Xiphisternum to Umbilicus, Umbilicus to pubic symphysis, Umbilicus to right and left iliac crest also at mid-thigh, mid ankle, mid-calf because of oedema over there. Clinical assessment measures showed gradual improvement. The outcome is mentioned in chart and also shown in graph no. 1 and graph no.2.

| Date     | Weight in kg | At umbilicus in cm | 1cm above umbilicus | 1cm below umbilicus | Xiphi to Umbilicus | Umbilicus to pubis |
|----------|--------------|--------------------|---------------------|---------------------|--------------------|--------------------|
| 18/12/19 | 73.3         | 99.5               |                     |                     | 24                 | 15                 |
| 19/12/19 | 70.7         | 101.5              | 102                 | 100                 | 24.5               | 16                 |
| 20/12/19 | 71.4         | 101.5              | 102                 | 100                 | 25                 | 16                 |
| 21/12/19 | 69.1         | 101.5              | 101                 | 100                 | 24.5               | 16                 |
| 22/12/19 | 69.5         | 102                | 102                 | 101                 | 24.5               | 16                 |
| 23/12/19 | 64.7         | 98                 | 99                  | 95                  | 24                 | 15                 |
| 24/12/19 | 62.6         | 100                | 99                  | 98                  | 25                 | 15                 |
| 25/12/19 | 61           | 95                 | 96                  | 95                  | 23                 | 15                 |
| 26/12/19 | 60.4         | 93                 | 94                  | 93                  | 22                 | 15                 |
| 27/12/19 | 59.2         | 90                 | 92                  | 91                  | 21.5               | 15                 |
| 28/12/19 | 59.9         | 90                 | 91                  | 90                  | 21                 | 14                 |
| 29/12/19 | 52.7         | 90                 | 90                  | 88                  | 22                 | 14                 |
| 30/12/19 | 60.4         | 92                 | 90                  | 88                  | 22                 | 15                 |



| Date  | Umbilicus to iliac crest in cm |      | Lower limbs measurements in cm |          |           |           |          |           |
|-------|--------------------------------|------|--------------------------------|----------|-----------|-----------|----------|-----------|
|       |                                |      | Right                          |          |           | Left      |          |           |
|       | Right                          | Left | Mid thigh                      | Mid calf | Mid Ankle | Mid thigh | Mid calf | Mid Ankle |
| 18/12 | 18                             | 19   | 34                             | 33.5     | 27        | 33        | 32       | 27        |
| 19/12 | 19                             | 19.5 | 33.5                           | 33       | 27        | 32        | 32       | 26.5      |
| 20/12 | 21                             | 22   | 33                             | 32       | 27        | 32        | 31       | 26.5      |
| 21/12 | 21                             | 22   | 47                             | 32       | 27        | 46.5      | 31       | 26        |
| 22/12 | 21                             | 22   | 47                             | 31       | 27        | 46.5      | 31       | 26        |
| 23/12 | 21                             | 21   | 46                             | 27       | 27        | 45        | 26       | 26        |
| 24/12 | 21                             | 21   | 45                             | 27       | 28        | 44        | 26       | 27        |
| 25/12 | 21                             | 20   | 41                             | 26       | 26        | 43        | 26       | 26        |
| 26/12 | 19                             | 18   | 43                             | 26       | 26        | 43        | 26       | 26        |
| 27/12 | 19                             | 18   | 42                             | 26       | 25        | 42        | 25       | 25        |
| 28/12 | 19                             | 19   | 43                             | 26       | 25.5      | 43        | 26       | 25.5      |
| 29/12 | 16                             | 17   | 42.5                           | 25.5     | 25.5      | 42.5      | 25.5     | 25.5      |
| 30/12 | 17                             | 18   | 43                             | 26       | 26        | 43        | 26       | 25.5      |



## DISCUSSION

As *Jalodara Vyadhi* is *Vatapradhana Tridoshas*. In the *Samprapti* (Pathogenesis) *Agnimandya* (Loss of appetite), *Srotorodha* (Blockage of channels), *Balakshaya* (Weakness) pathogenesis are going on to break that pathogenesis the following treatment were adopted. From the date of admission 18<sup>th</sup> Dec. started with *Pachak Vati* in one TDS dose with *Koshna Jala* and given in *Vyanoudana Kala*. It helped to improve digestion and promoted to absorption of nutrients. It reduced aggravated *Tridoshas* and improved digestion by increasing peristaltic movement. On 2<sup>nd</sup> day, *Laghu Sutashekhar* 500mg was given for *Udarshoola*, *Udardaha* and *Kandu*.

*Virechana* is expected to remove vitiated *Pitta Dosha*<sup>[12]</sup>. *Haritaki* has the property of regeneration of hepatocytes. It is *Anulomak* and helps in relieving of the bacterial over growth in the intestine and it reduces the conversion time of the urea into ammonia and reduces the chances of the hepatic encephalopathy.

From 19<sup>th</sup> to 21<sup>st</sup>, *Haritaki Churna* 5gm was given with 50ml *Koshna Dugdha* in *Abhakta Kala* as a *Nitya Virechana*, then he had total 5 *Vegas*. Dose has been reduced to 3gm with 30ml *Koshna Dugdha*, was given on 22<sup>nd</sup> and 23<sup>rd</sup> because he suffered from more *Vegas* and faced to *Daurabalya*. Due to this dose, he undergone with 7 *Vegas*. On 24<sup>th</sup> and 25<sup>th</sup>, 5gm dose of *Churna* was given then he had 6-7 *Vegas*. On 26<sup>th</sup>-27<sup>th</sup>, 3gm dose was given, then he had 3-4 *Vegas*. On 28<sup>th</sup>-29<sup>th</sup> 5gm dose was given due to which he had 7 to 8 *Vegas*.

On 21<sup>st</sup> to 30<sup>th</sup>, combination of *Arogyavardhini Vati*, *Daruharidra*, *Sharpunkha Churna* (each 500mg) was given. It acts on liver and spleen<sup>[13]</sup>. *Sharpunkha* and *Daruharidra* have *Tikshna*, *Ruksha Gunas* and *Ushna Viryatmaka*, *Katu Vipaki*<sup>[14]</sup>. *Tikshna*, *Ushna Guna* enhances *Agni*. By its *Ushna*, *Tikshna* and *Ruksha Guna*, it removes *Strotosanga* and also acts on *Udaka* and also it helps to remove portal hypertension. Main content of

*Arogyavardhini Vati* is *Kutaki* which acts as *Pitta Virechaka* and shows action on *Yakrita*<sup>[15,16]</sup>. This is also helpful in removing the obstruction of hepatobiliary channels and correcting by hyperbilirubinaemia. *Cucurbitacin* exhibited liver protective, anti-inflammatory activities. *Kutkin glycosidal bitter principle* of *Kutaki* exhibited hepatoprotective activity in Carbon tetrachloride<sup>[17]</sup>. In this study, subject had mild Hepatomegaly so *Sharpunkha* and *Arogyavardhini* used because they acts as *Yakrituttejaka*.

During 21<sup>st</sup> to 30<sup>th</sup> *Avipattikar Churna* used as *Dahashamaka* and *Pitta Virechaka*<sup>[18]</sup>.

*Guduchi*, *Katuki*, *Nimba*, *Bhrigraja*, *Amalaki*, *Punarnava*, *Triphala*, *Daruharidra* are the contents of *Guduchyadi Churna*.

They have *Tikta Pradhana* and *Kashaya Rasa Anubhandhi* with *Ushna Virya* and *Ruksha*, *Ushnathmak* properties, which shows *Kaphapittaghna* which is primary indication for *Udara* treatment. Due to its *Gunas*, it helps in absorption of extra peritoneal fluid, which plays an important role by *Kleda Shoshana*, *Agni-Dipana*, *Strotomukhvishodhana*, *Yakrita-uttejaka*. Also, this is helpful in other associated complaints of *Udara*.

*Punarnava Churna* has anti-inflammatory, anti-bacterial action and useful in inflammatory renal diseases as well as nephrotic syndrome in case of ascites resulting from early cirrhosis of liver and chronic peritonitis. It helps to increase the urine output and helps to remove oedema<sup>[19]</sup>.

*Bhringraja* is best tonic for liver. It works on Hepatitis and spleen enlargement. The herb contains *Wedelolactone* and *diethyl Wedelolactone* which showed a dose dependent effect against Carbon tetrachloride, *d galactosamine* or *phalloidin* induced cytotoxicity in primary cultured at hepatocytes and exhibited potent antihepatotoxic properties<sup>[20]</sup>. The whole plant showed effects on liver cell regeneration and an immunoactive



property was observed against surface antigens of the HBV.

*Guduchi* balances *Vata* and *Pitta*. It has the unusual characteristic of being heating while simultaneously removing excess *Pitta* from the body and reducing inflammation. It is helpful in repairing fibrosis and regenerating liver tissue. It also plays important role in normalisation of altered liver functions (ALT, AST)<sup>[21]</sup>.

*Daruharidra* is hepatoprotective in nature and fights against liver toxicity.

On 22<sup>nd</sup>, *Shankh Vati* 250mg was given with *KoshnaJala* in *Vyanoudana Kala* as he was suffering from *Udaradhmana*.

During 23<sup>rd</sup> to 30<sup>th</sup>, *Kamdudha Rasa* 1gm was given in *Vyanoudana Kala* as he was suffering from *Udardaha*.

During 26<sup>th</sup> to 30<sup>th</sup>, *Hignavashataka Churna* 125mg was given with *Mudga Yusha* as *Muhurmuhu* for enhancement of *Agni*.

### **Pathyapathya**

In *Jalodara*, *Pathyapathya* also plays avital role. Without diet restriction, there is no use of medicine. So, *Godugdha*, *Mudhga Yusha* were advised because he had *Agnimandya*<sup>[22]</sup>. According to modern, in Ascites there is deficiency of Vitamins and nutritive values. Cow milk was given because it has greater values of nutrients and Vitamins which was need of patient. Salt and water were totally

restricted which is considered as best solution. As salt and water increases abdominal fluid quantity by osmosis process.

By above treatment and *Pathyapathya* subject had shown significant improvement in weight, abdominal girth, measurement from Xiphisternum to umbilicus, Umbilicus to iliac crest and measure mental changes in lower limbs which is explained in supplementary 2.

### **CONCLUSION**

In *Udara Vyadhi*, *Tridoshas* are involved. So, it is necessary to break down the pathogenesis. In contemporary science, only Diuretics and Paracentesis is mentioned. But recurrence is more so this case was managed by only *Ayurvedic* Medicines. As patient was having complaints of *Balakshaya* (weakness) along with *Agnimandhya* (loss of appetite) which was got to normal state by advising *Dugdhapana* (drinking of milk) with *Deepana & Pachana Aushadhis*.

To remove of accumulated fluid *Nitya Virechana* was given and it gives best result by decreasing weight, abdominal girth and in measurement of lower limbs by decreasing oedema. To break up the *Sanga* of all *Doshas* and retained fluid and separate them, *Virechana* is necessary. *Yakrita* is the *Mula Sthana* of *Rakta*. *Rakta Pitta* has *Ashraya* and *Ashrayi Sambhadha*, hence, *Virechana* is the best treatment for elimination of *Pitta Dosh*.

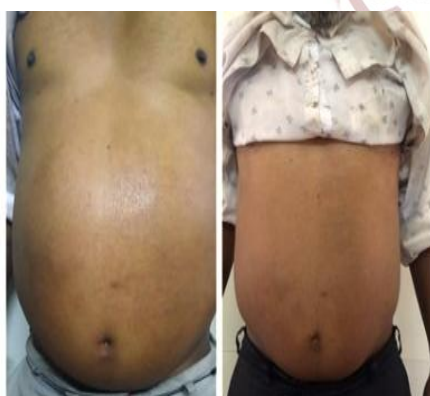

Figure 1: Abdominal Girth

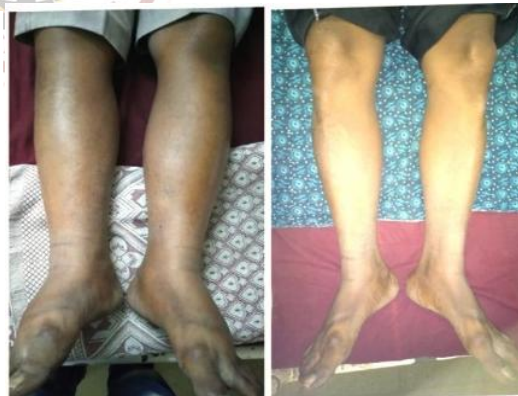

Figure 2: Pedal Oedema

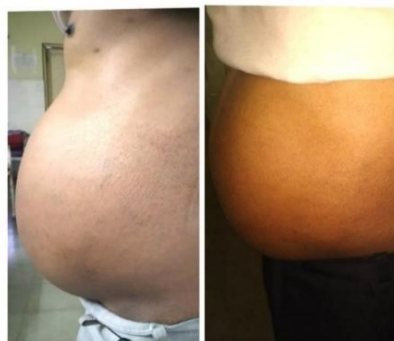

Figure 3: Left Lateral View

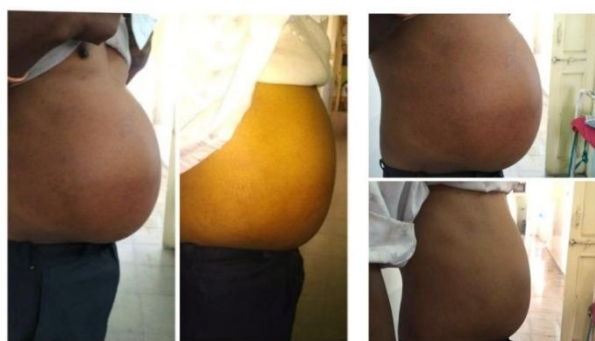

Figure 4: Right Lateral View

## REFERENCES

- Staff writer (2010). Ascites. Dictionary.com: An Ask.com Service. Oakland, CA: IAC. Retrieved December 14, 2017.
- Fernandez-Esparrach G, Sanchez-Fueyo A, Gines P, Uriz J, Quintó L, Ventura PJ, Cárdenas A, Guevara M, Sort P, Jimenez W, Bataller R, Arroyo V, Rodés J: A prognostic model for predicting survival in cirrhosis with ascites. *J. Hepatol.* 34 (1): 2001;46-52,
- Ascites-Hepatic and Biliary disorders Merck Manuals Professional Edition. May 2016, Retrieved 14 December 2017.
- Kotihal M, Muttappa T, Vasantha B, Sandrima KS. Critical analysis of Jalodara (Ascites) - A review. *J Ayurveda Integr Med Sci.* 2017; 2:150-3.
- Singh R. N. Charaka Samhita, Chaukhambha Publications, New Delhi, Reprint Edition, Chikitsasthana, 2016: 13/24: p.492.
- Singh R. N. Charaka Samhita, Chaukhambha Publications, New Delhi, Reprint Edition, Vimansthana, 2016: 15/5.
- Harisastri Prasadakara B.: Ashtang Hridaya, Chaukhambha Orientalia, Varanasi, Ashtang Hriday Ayurved Rasayan Commentary, Nidansthan 1998: 12/1.
- Shastri S. Yogratnakar, Chaukhambha Publications, Varanasi, editor. Reprint Edition, Uttarardha, 2018: 15/3: p.102.
- Singh R.N. Charaka Samhita, Chaukhambha Publications, New Delhi, Reprint Edition, Chikitsasthana, 2016: 13/11: p.491.
- Singh R. N. Charaka Samhita, Chaukhambha Publications, New Delhi, Reprint Edition, Chikitsasthana, 2016: 13/10: p.491.
- Singh R.N. Charaka Samhita, Chaukhambha Publications, New Delhi, Reprint Edition, Chikitsasthana, 2016: 13/98: p.491.
- Jadhav DK. An Ayurvedic approach in the management of Jalodara (Ascites): A case study. *Int J Ayurveda Res.* 2016;1:90-91.
- Acharya Sharma P, Dravyaguna Vidyana, Chaukhambha Publications, New Delhi, editor. Reprint Edition, Vol II, 2017: 6: p.554.
- Acharya Sharma P, Dravyaguna Vidyana, Chaukhambha Publications, New Delhi, editor. Reprint Edition, Vol II, 2017: 6: p.537.
- Pandey GS, Bhavprakash Nighantu of Bhavamisra, Goduchyadi Varga, Chaukhambha Bharati Academy, Varanasi, editor, 2010: 3/210: p.393.
- Government of India, Ministry of Health and Family Welfare; The Ayurvedic Formulary of India. Rasayoga Arogyavardhini Gutika; Revised English Edition, New Delhi: Part-1, 2003: 20/4 p. 258.
- Vaidya AB, Antarkar DS, Doshi JC, et al. Picrorhiza kurroa (Kutki) Royle ex Benth as a hepatoprotective agent- experimental & clinical studies. *J Postgrad Med.* 1996;42(4): 105-108.
- Shastri R, Bhaisajyaratnavali of Shri Govinddas, edition 18, p.922.
- D.Bhowmik, Traditional Indian Herbs Punarnava and Its Medicinal Importance, *J Pharmacognosy Phytochem.* 2012; 1(1),52-8.
- Jahan, Rownak et al. Ethnopharmacological Significance of Eclipta alba (L.) Hassak (Asteraceae). *International scholarly research notices vol.2014 385969.* 29 Oct.2014, doi: 10.1155/2014/385969.
- Karkal YR, Bairy LK. Safety of aqueous of *Tinospora cordifolia* (Tc) in healthy volunteers: A double blind randomised placebo controlled study. *Iranian J Pharmacol Therap.* 2007; 6:59-61.
- Sharma, P.V Chakradatta, Text with English translation published by Chaukhambha publishers, Varanasi; 1998: p.314.

**Cite this article as:**

S.R.Tarapore, R.A. Shaha, J.D.Khot. Management of Ascites (Jalodara) through Ancient System of Medicine- A Case Report. *AYUSHDHARA*, 2020;7(4):2798-2804.

**Source of support: Nil, Conflict of interest: None Declared**

Disclaimer: AYUSHDHARA is solely owned by Mahadev Publications - A non-profit publications, dedicated to publish quality research, while every effort has been taken to verify the accuracy of the content published in our Journal. AYUSHDHARA cannot accept any responsibility or liability for the articles content which are published. The views expressed in articles by our contributing authors are not necessarily those of AYUSHDHARA editor or editorial board members.